

## What's Your Diagnosis?

### Signalment

Species: Canine  
Breed: Dachshund  
Sex: Male intact  
Age: 10.5 yrs.

### Presenting Complaint

Mass noted in the ventral neck region. Clinical signs include drinking more water, urinating more, and producing an intermittent snoring noise on inspiration.

### History and Physical Exam

- Mass in the left ventral neck region that was fixed to the underlying tissues.
- Grade 3/6 left basilar systolic heart murmur.
- Two subcutaneous masses were noted; a 2cm mass on the lateral aspect of the right shoulder and a 1cm mass in the medial right axillary region.

### Plan

- Aspirate of the ventral neck mass- Found features consistent with epithelial neoplasia and mild features of malignancy. These findings were suggestive of a thyroid adenocarcinoma.
- CBC- no abnormalities
- Chemistry- BUN: Decreased at 5 mg/dl.  
Cr: Decreased at 0.4 mg/dl - Not clinically significant.
- Total T4- 56.1 nmol/L (Normal: 10-45.5 nmol/L)
- Thoracic radiographs.

### Radiograph Interpretation

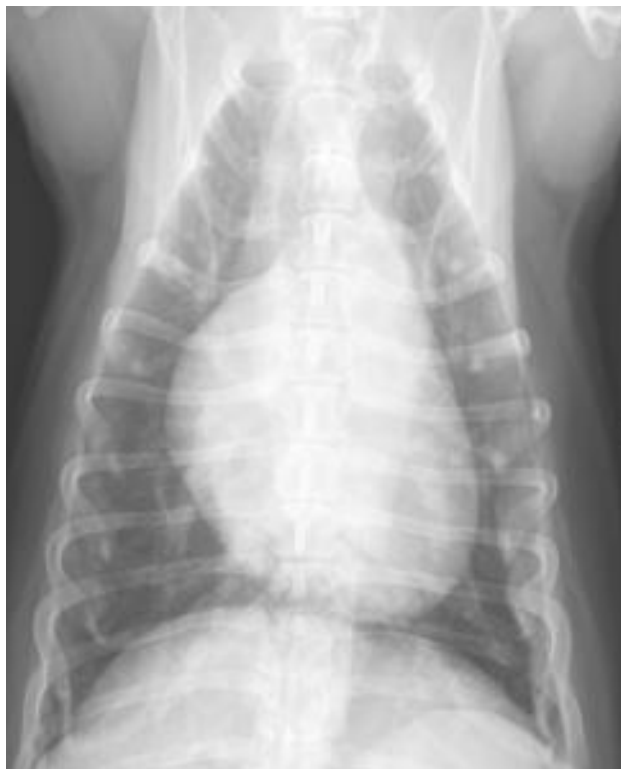

Figure 1: Ventrodorsal

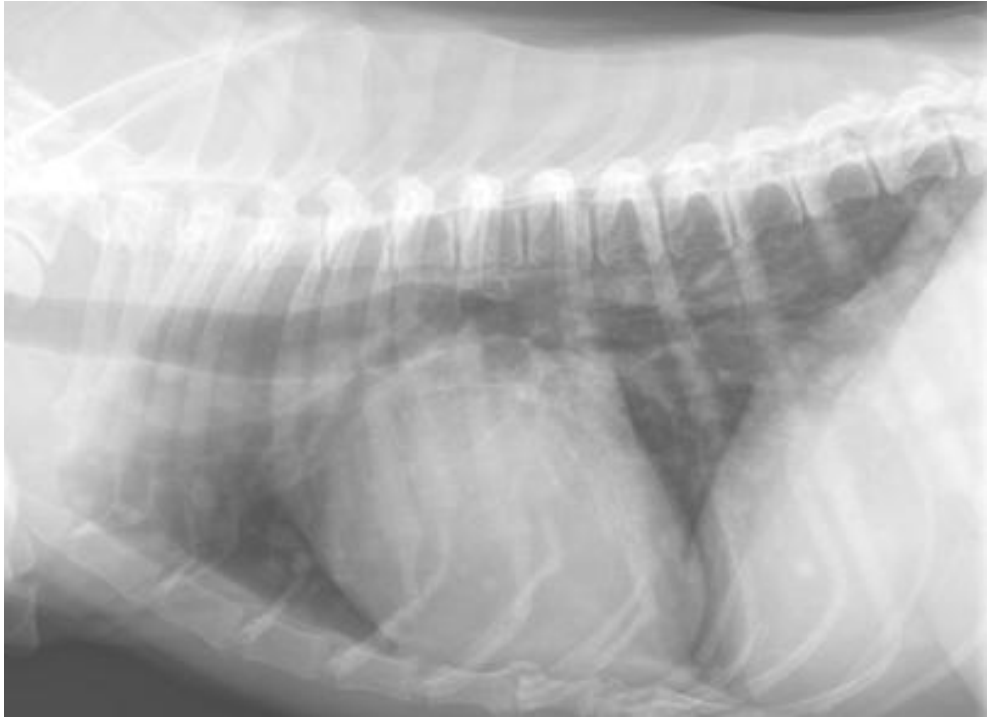

Figure 2: Right Lateral

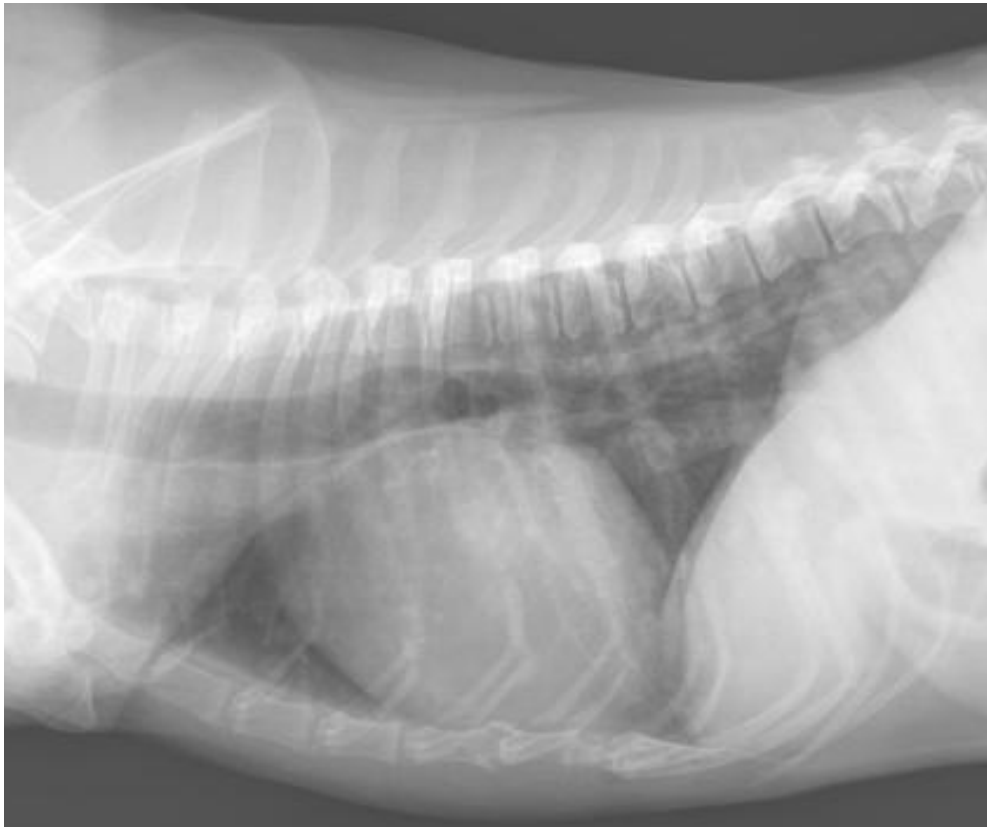


Figure 3: Left Lateral